

# Small cell carcinoma originating from the cavernous sinus

Hiroshi Nakaguchi · Akira Matsuno ·  
Satoru Miyawaki · Mineko Murakami ·  
Masatoshi Yamada · Kazuhito Yamazaki · Yasuo Ishida

Received: 19 November 2008 / Accepted: 21 April 2009 / Published online: 13 May 2009  
© Springer-Verlag 2009

## Abstract

**Background** We report a rare case of small cell carcinoma originating from the right cavernous sinus in a 55-year-old male. The patient had sudden onset of right abducens palsy following right oculomotor palsy.

**Methods** Post-contrast T1-weighted MRI revealed a mass lesion of 3-cm maximum size occupying the right cavernous sinus and extending to the right middle cranial fossa. After biopsy via the frontozygomatic approach, one radiosurgery treatment was followed by four cycles of chemotherapy (cisplatin together with VP-16 therapy), after which the lesion diminished dramatically in size.

**Results** Complete remission has currently been achieved. The patient recovered from the extraocular muscle paresis and returned to his previous work. Although it is considered possible that small cell carcinoma can occur wherever neuroendocrine cells exist, a lesion originating in the cranium is extremely rare. To the best of our knowledge, this is the first report of small cell carcinoma of intracranial origin.

cell carcinoma have brain metastases [1, 34, 35]. Almost 30% of patients with small cell carcinoma enter complete remission, but only 0 to 5% of patients with extensive-stage disease are cured [5, 6, 15, 16, 29, 33]. Small cell carcinoma is reported to most commonly originate from the lung, and rarely from the intestine [4, 9, 12, 17, 21], liver, breast [28], larynx, parotid gland, genitourinary system [3, 11, 17, 23], upper respiratory system [18], thymus, peritoneum [22], and bone [7, 8, 13, 19, 26, 30]; however, a MEDLINE search revealed no reports of small cell carcinoma of intracranial origin other than in the nasal sinus [10, 14, 38].

We observed a case of small cell carcinoma that originated from the right cavernous sinus and extended into the right middle cranial fossa to involve the internal carotid artery, with right abducens palsy as an initial symptom. In this report, we present the detailed clinical course, various neuroimaging findings, and the result of pathological examination of this rare disease.

## Introduction

Small cell carcinomas account for 15 to 20% of lung carcinomas, and approximately 10% of patients with small

## Case presentation

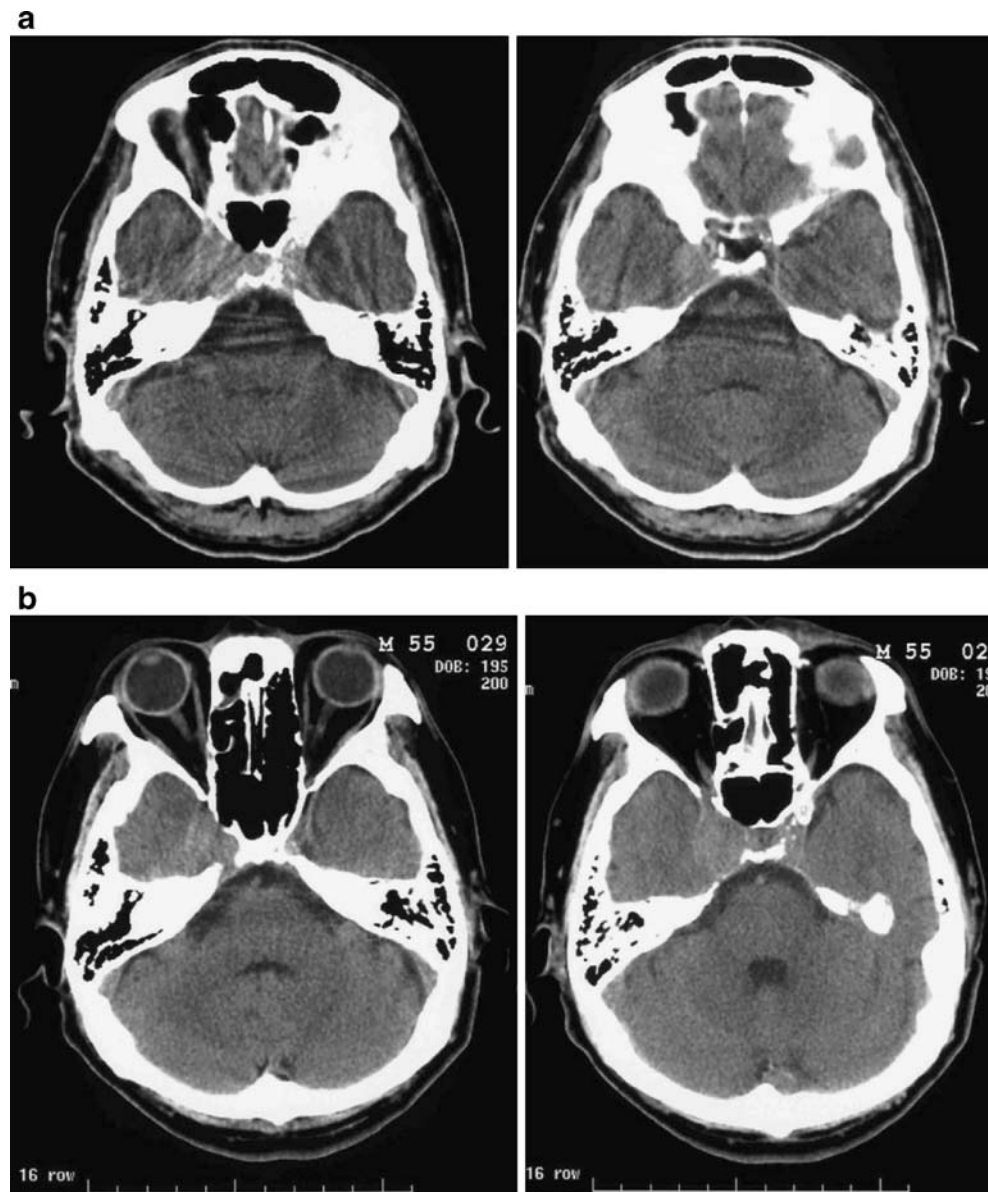
A 55-year-old man had a sudden onset of right abducens palsy following right oculomotor palsy. Magnetic resonance imaging (MRI) revealed a lesion occupying the right cavernous sinus and right middle temporal fossa, and he was referred for neurosurgical consultation. The patient was fully conscious and had no paresis of the extremities, sensory disturbance, or gait disturbance. He had right incomplete abducens palsy and right complete oculomotor palsy. There was no other cranial nerve palsy.

Computed tomography (CT) revealed an iso-dense mass occupying the right cavernous sinus, extending to the right middle cranial fossa, with a maximum size of 3 cm (Fig. 1).

H. Nakaguchi (✉) · A. Matsuno · S. Miyawaki · M. Murakami  
Department of Neurosurgery,  
Teikyo University Chiba Medical Center,  
Ichihara, Japan  
e-mail: hnakaguchi@hi-ho.ne.jp

M. Yamada · K. Yamazaki · Y. Ishida  
Department of Pathology,  
Teikyo University Chiba Medical Center,  
Ichihara, Japan

**Fig. 1** **a** CT (pre-contrast) demonstrates a mass in the middle cranial fossa with deformation of the wall of the sphenoid bone. **b** CT (post-contrast) shows homogeneous enhancement of the mass



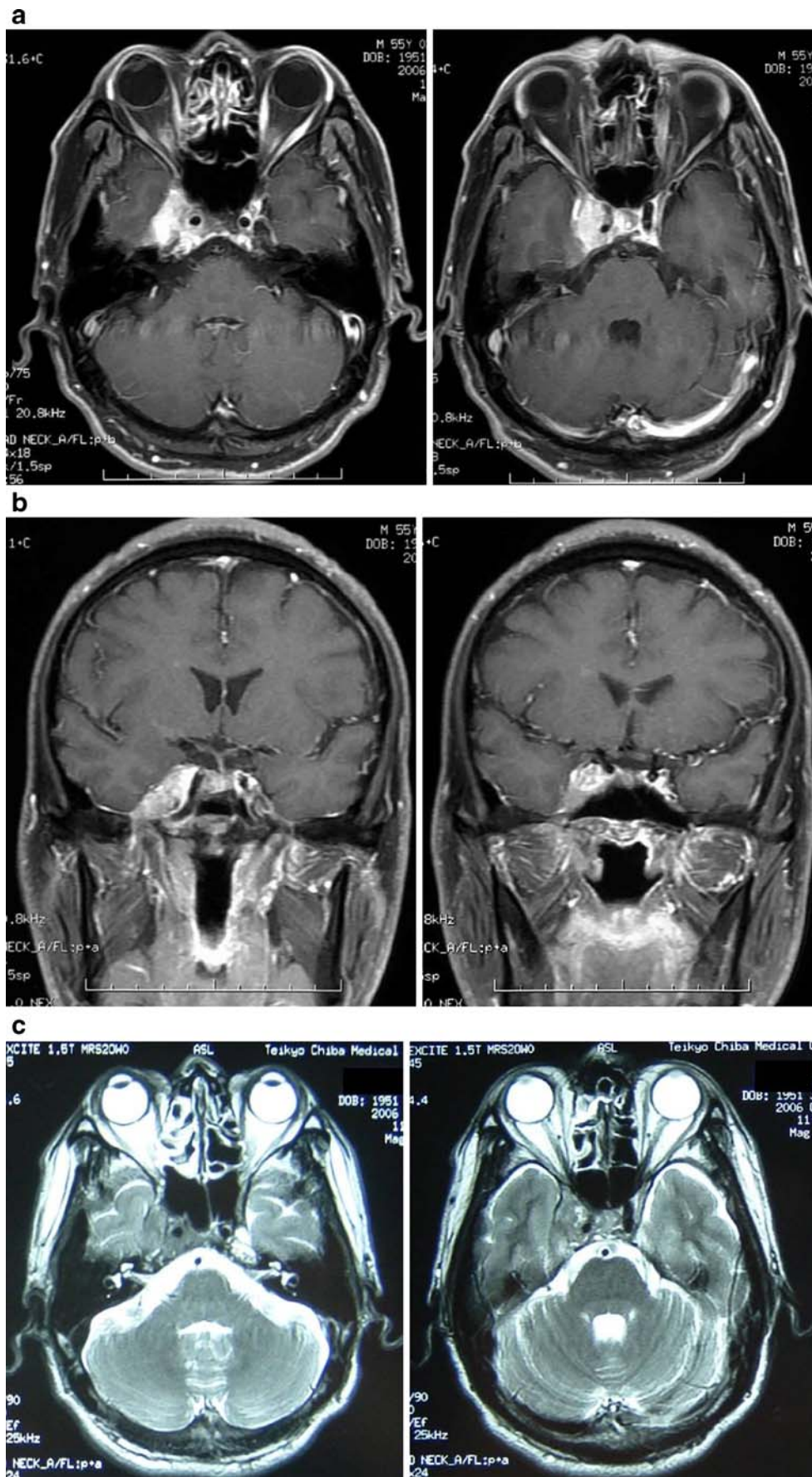
On MRI, T1-weighted (T1WI) and T2-weighted images (T2WI) depicted the lesion as a heterogeneous mass containing a centrally located flow void because of the right internal carotid artery, indicating that the right internal carotid artery was completely involved (Fig. 2c). Post-contrast T1WI demonstrated homogeneous enhancement of the lesion by gadolinium phosphate (Fig. 2a,b). A right internal carotid arteriogram showed several fine arterioles from the right meningohypophyseal artery that were considered to be feeder vessels and retention of contrast medium in the tumor from the late arterial to the late venous phases (Fig. 3). Thallium scintigrams showed prominent uptake of radioisotopes by the lesion; the retention index was calculated as 0.95, which indicates a lesion with malignant features.

### Surgery

We performed biopsy of the lesion. The lesion was revealed extradurally by the fronto-zygomatic approach, the dura between the second and third division of the trigeminal nerve was cut, and a small amount of tumor was carefully and safely removed using fine tumor forceps.

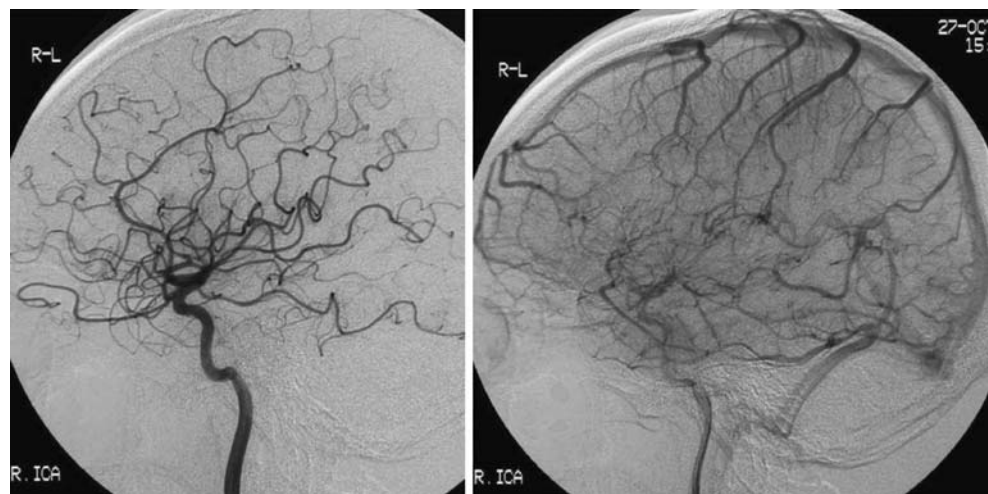Histological examination revealed that the tumor was comprised of small round or oval cells with hyperchromatic nuclei, scant cytoplasm, and inconspicuous nucleoli, although

**Fig. 2** **a** Axial T1WI MRI (post-contrast) shows a homogeneously enhancing mass that extends from the right cavernous sinus to the middle cranial fossa. **b** Coronal T1WI MRI (post-contrast) reveals that the mass completely involves the right carotid artery. **c** Axial T2WI MRI shows an iso-intense mass in the cavernous sinus





**Fig. 3** Digital subtraction angiography (DSA) lateral views; venous and arterial phases reveal mild tumor staining in the cavernous sinus



crush artifacts predominated (Fig. 4a). The tumor showed a trabecular growth pattern and invaded to the fibrous stroma desmoplastically. Molding of tumor cells was focally observed.

Immunohistochemically, the tumor cells were positive for epithelial markers, including cytokeratin AE1/AE3, and Ber-EP4 and for neuroendocrine differentiation markers, including synaptophysin, chromogranin A (Fig. 4b), CD56 (Fig. 4c), and NSE, and for bcl-2. They were negative for TTF-2 and WT-1. The Ki-67 immunoreactivity labeling index was more than 35%.

Electron micrographs of tumor cells showed that cytoplasmic neurosecretory granules varied from 100–200 nm in diameter (Fig. 4d). They were roundly structured and consisted of a central dense core, a peripheral lucent halo, and a single delimiting outer membrane.

The morphological and immunohistochemical findings of the tumor cells were compatible with a neuroendocrine neoplasm with epithelioid features, such as a carcinoid tumor or a neuroendocrine carcinoma. Among them, the findings of immunohistochemical examinations and neuro-radiological examinations suggested small cell carcinoma as the most appropriate diagnosis.

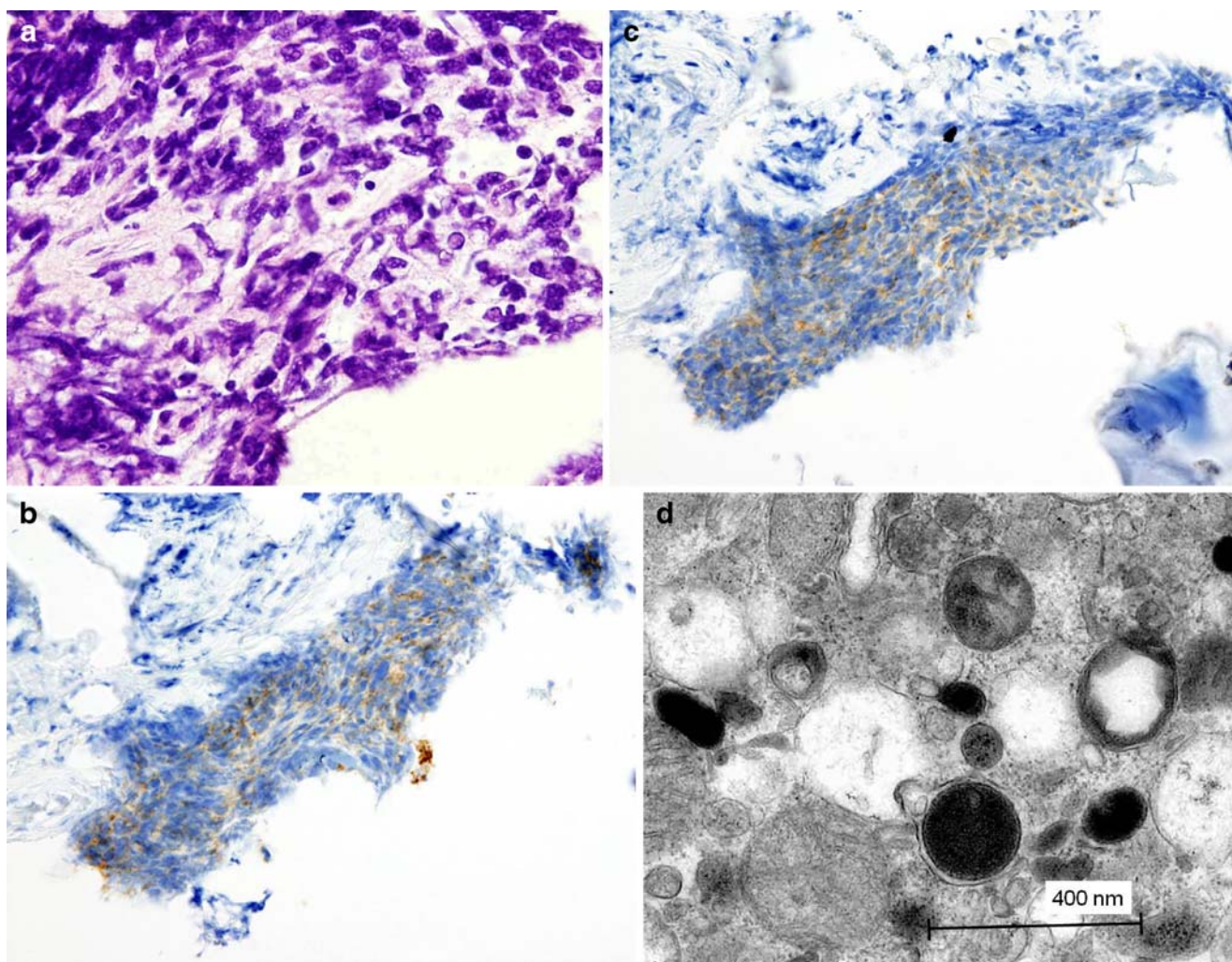
### Postoperative course and treatment

One week after surgery, whole-body FDG-positron emission tomography (FDG-PET) revealed no hot lesions other than the right middle cranial fossa mass. Upper gastrointestinal endoscopy and contrasted CT of the abdomen and chest showed no abnormal lesions in the chest or abdomen. No previous reports described small cell carcinoma of intracranial origin, and we could not obtain information regarding its treatment from any previous reports or texts. Because the pathological findings of this tumor resembled those of lung origin, we determined a treatment strategy including chemo-

radiotherapy based on that for small cell carcinoma originating from the lung [31, 36, 37].

Stereotactic radiation therapy (gamma knife surgery) was selected for this case because the tumor was located in the cavernous sinus, and no extradural invasion was found during biopsy. A chemotherapy protocol using cisplatin together with VP-16, as used against small cell carcinomas originating from the lung, was chosen for this case and was administered intravenously four times with an interval of 28 days. As the dose per course of chemotherapy, cisplatin calculated as 80 mg/m<sup>2</sup> using body surface area (m<sup>2</sup>) and VP-16 calculated as 100 mg/m<sup>2</sup> were injected intravenously. Leukocytopenia occurred 3 weeks after the first chemotherapy (the concentration of neutrophilic leukocytes decreased to 500/mm<sup>3</sup>), and granulocyte colony-stimulating factor (G-CSF) was administered intravenously for 2 consecutive days, after which the concentration of WBCs increased to the normal range in several days.

After four courses of chemotherapy had been completed, post-contrast T1-weighted MRI revealed a prominent reduction of tumor size to almost one-third of the initial tumor volume. We performed whole-body FDG-PET studies three times: the first study was performed 1 week after surgery, the second a few days after the last chemotherapy, and the third at 10 months after the first FDG-PET. FDG-PET depicted the tumor in the cavernous sinus as a prominent hot area on the first study; on the second and third studies, no hot lesion was revealed in the middle cranial fossa, but a slightly hot area was detected in the right pharynx. Otolaryngologists performed intrapharyngeal endoscopy and post-contrast CT scans through the pharynx, but no morphological abnormality was observed on the surface or under the mucosal membrane of the pharynx; it was concluded that no lesion existed in the right pharynx and that the hot area on FDG-PET appeared to represent inflammatory change in the pharyngeal submucous membrane tissue following radiosurgery.



**Fig. 4** **a** Histological findings of surgically obtained specimen. Tumor with crush artifact is presented. Hematoxylin and eosin (HE) stain, original magnification  $\times 100$ . **b**, **c** Immunohistochemistry for neuroendocrine differentiation indicators. Tumor cells show diffuse

cytoplasmic reactivity of CD 56 (4-B) and chromogranin A (4-D) (original magnification  $\times 400$ ). **d** Electron micrograph of tumor cell presents cytoplasmic neurosecretory granules

There was gradual recovery in the right extra-ocular movement disturbance from approximately 1 week after radiosurgery, and the patient now complains only of mild diplopia in the upper right visual field. He has been reinstated in his previous job as a construction worker. Currently, 2 years and 5 months after the last chemotherapy, he continues to visit the outpatient neurosurgical department every 3 months and has received follow-up studies including contrast-enhanced MRI every 3 to 6 months and a systemic FDG-PET study every 6 months; these studies suggest no signs of recurrence (Fig. 5).

## Discussion

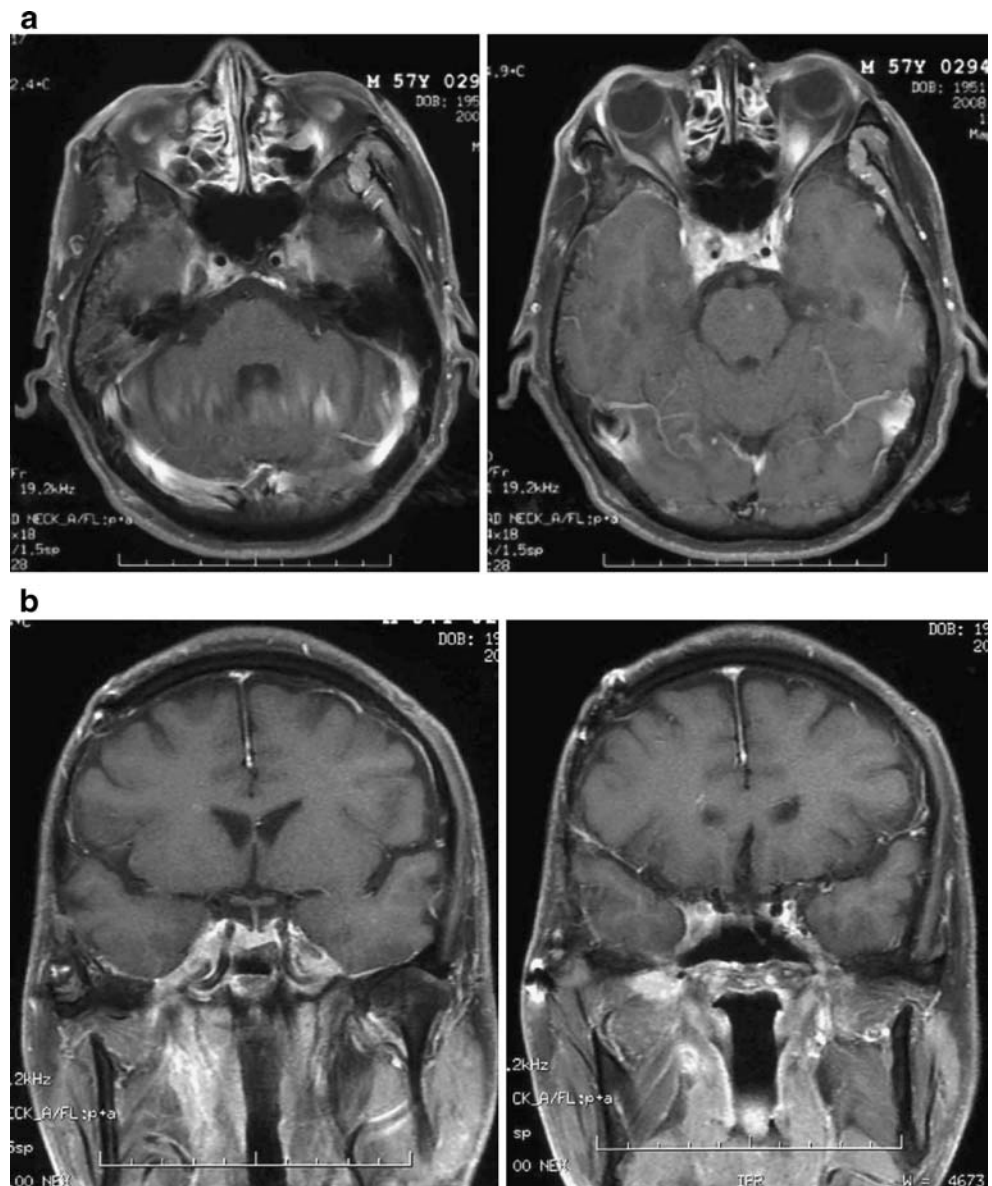
As pathological findings, small cell carcinoma is characterized by a small and highly dyed nucleus (about two to

three times that of a normal lymphocyte nucleus) with a small amount of cytoplasm [27]. The origin of small cell carcinoma is considered to be a stem cell or differentiation-committed stem cell derived from neuroendocrine cells of the epithelium (endoderm); small cell carcinoma is considered to potentially occur wherever neuroendocrine cells exist.

The WHO histological classification of primary lung tumors (1982) classified small cell carcinoma into three types: oat cell carcinoma, intermediate cell carcinoma, and combined oat cell carcinoma. This classification is considered to be problematic because a strict differential diagnosis among these three types is difficult pathologically and because the same therapy strategy is chosen for each subtype. One to two percent of all carcinomas are generally considered to be initially diagnosed following symptoms caused by local damage from metastatic lesions, and almost



**Fig. 5** **a** Axial T1WI MRI (post-contrast) performed 6 months after the last chemotherapy demonstrates a prominent decrease in tumor volume. **b** Coronal T1WI MRI (post-contrast) performed 2 years after the last chemotherapy demonstrates a prominent decrease in tumor volume



10% of all small cell carcinomas are considered to show brain metastasis [24]. Therefore, in this case we first considered whether the intracranial lesion might be a metastatic tumor [20] and searched for lesions in other sites. No other lesions were found, and we therefore supposed that in this case the small cell carcinoma must have originated from neuroendocrine cells of the wall of the cavernous sinus. However, we are carefully following the post-chemoradiotherapeutic course of the patient because the possibility of an undiscovered primary lesion still has not been ruled out.

In a literature search using MEDLINE, no reports were found regarding intracranial primary small cell carcinoma. Lung small cell carcinoma often metastasizes to the brain [32]; cases with brain metastasis are classified as belonging

to stage 4. Life expectancy is relatively short for stage 4, and it has been reported that the 5-year survival rate was 0 to 5% for stage 4 patients. In contrast, patients with lung small cell carcinoma who have no metastasis to other organs and who receive appropriate treatment immediately, including extended resection of the tumor and completion of chemo-radiotherapy, are expected to have long, tumor-free lives, with some patients achieving complete remission.

In the present case, the lesion originated from the cavernous sinus without invasion to surrounding regions or metastasis to other organs, and chemo-radiotherapy was completed. The patient achieved complete remission at 2.4 years from the onset [31, 36, 37]. It is considered that this single lesion of small cell carcinoma responded well to chemo-radiotherapy even though the lesion did not originate from the lung.

## References

- Aupérin A, Arriagada R, Pignon JP, Le Péchoux C, Gregor A, Stephens RJ, Kristjansen PE, Johnson BE, Ueoka H, Wagner H, Aisner J (1999) Prophylactic cranial irradiation for patients with small-cell lung cancer in complete remission. Prophylactic Cranial Irradiation Overview Collaborative Group. *N Engl J Med* 341(7):476–484. doi:10.1056/NEJM199908123410703
- Cheran SK, Herndon JE 2nd, Patz EF Jr (2004) Comparison of whole-body FDG-PET to bone scan for detection of bone metastases in patients with a new diagnosis of lung cancer. *Lung Cancer* 44(3):317–325. doi:10.1016/j.lungcan.2003.11.008
- Cicin I, Karagol H, Uzunoglu S, Uygun K, Usta U, Kocak Z, Caloglu M, Saynak M, Tokatli F, Uzal C (2007) Extrapulmonary small-cell carcinoma compared with small-cell lung carcinoma: a retrospective single-center study. *Cancer* 110(5):1068–1076. doi:10.1002/cncr.22887
- Demellawy DE, Samkari A, Sur M, Denardi F, Alowami S (2006) Primary small cell carcinoma of the cecum. *Ann Diagn Pathol* 10(3):162–165. doi:10.1016/j.anndiagpath.2005.09.008
- Fetscher S, Brugger W, Engelhardt R, Kanz L, Hasse J, Frommhold H, Lange W, Mertelsmann R (1999) Standard- and high-dose etoposide, ifosfamide, carboplatin, and epirubicin in 100 patients with small-cell lung cancer: a mature follow-up report. *Ann Oncol* 10(5):561–567. doi:10.1023/A:1026453922931
- Fetscher S, Brugger W, Engelhardt R, Kanz L, Hasse J, Frommhold H, Wenger M, Lange W, Mertelsmann R (1997) Dose-intense therapy with etoposide, ifosfamide, cisplatin, and epirubicin (VIP-E) in 100 consecutive patients with limited- and extensive-disease small-cell lung cancer. *Ann Oncol* 8(1):49–56. doi:10.1023/A:1008232329498
- Galanis E, Frytak S, Lloyd RV (1997) Extrapulmonary small cell carcinoma. *Cancer* 79(9):1729–1736. doi:10.1002/(SICI)1097-0142(19970501)79:9<1729::AID-CNCR14>3.0.CO;2-#
- Haider K, Shahid RK, Finch D, Sami A, Ahmad I, Yadav S, Alvi R, Popkin D, Ahmed S (2006) Extrapulmonary small cell cancer: a Canadian province's experience. *Cancer* 107(9):2262–2269. doi:10.1002/cncr.22235
- Ihtiyar E, Algin C, Isiksoy S, Ates E (2005) Small cell carcinoma of rectum: a case report. *World J Gastroenterol* 11(20):3156–3158
- Janjan NA, Campbell B, Wilson JF, Zellmer D (1989) Small cell undifferentiated carcinoma of the maxillary sinus: technical considerations for radiation therapy. *Med Dosim* 14(4):273–276
- Karpman E, Goldberg Z, Saffarian A, Gandour-Edwards R, Ellison LM, deVere White RW (2004) Analysis of treatment for small cell cancer of the bladder and report of three cases. *Urology* 64(3):494–498. doi:10.1016/j.urology.2004.04.038
- Khansur TK, Routh A, Mihas TA, Underwood JA, Smith GF, Mihas AA (1995) Syndrome of inappropriate ADH secretion and diplopia: oat cell (small cell) rectal carcinoma metastatic to the central nervous system. *Am J Gastroenterol* 90(7):1173–1174
- Kim JH, Lee SH, Park J, Kim HY, Lee SI, Nam EM, Park JO, Kim K, Jung CW, Im YH, Kang WK, Lee MH, Park K (2004) Extrapulmonary small-cell carcinoma: a single-institution experience. *Jpn J Clin Oncol* 34(5):250–254. doi:10.1093/jjco/hyh052
- Kim KO, Lee HY, Chun SH, Shin SJ, Kim MK, Lee KH, Hyun MS, Bae SH, Ryou HM (2006) Clinical overview of extrapulmonary small cell carcinoma. *J Korean Med Sci* 21(5):833–837
- Kristensen CA, Kristjansen PE, Hansen HH (1992) Systemic chemotherapy of brain metastases from small-cell lung cancer: a review. *J Clin Oncol* 10(9):1498–1502
- Kristjansen PE, Soelberg Sørensen P, Skov Hansen M, Hansen HH (1993) Prospective evaluation of the effect on initial brain metastases from small cell lung cancer of platinum-etoposide based induction chemotherapy followed by an alternating multi-drug regimen. *Ann Oncol* 4(7):579–583
- Lee SS, Lee JL, Ryu MH, Chang HM, Kim TW, Kim WK, Lee JS, Jang SJ, Khang SK, Kang YK (2007) Extrapulmonary small cell carcinoma: single center experience with 61 patients. *Acta Oncol* 46(6):846–851. doi:10.1080/02841860601071893
- Lin IH, Hwang CF, Huang HY, Chien CY (2007) Small cell carcinoma of the nasopharynx. *Acta Otolaryngol* 127(2):206–208. doi:10.1080/00016480500401027
- Lo Re G, Canzonieri V, Veronesi A, Dal Bo V, Barzan L, Zancanaro C, Trovò M (1994) Extrapulmonary small cell carcinoma: a single-institution experience and review of the literature. *Ann Oncol* 5(10):909–913
- Lobins R, Floyd J (2007) Small cell carcinoma of unknown primary. *Semin Oncol* 34(1):39–42. doi:10.1053/j.seminoncol.2006.10.027
- Medgyesy CD, Wolff RA, Putnam JB Jr, Ajani JA (2000) Small cell carcinoma of the esophagus: the University of Texas M. D. Anderson Cancer Center experience and literature review. *Cancer* 88(2):262–267. doi:10.1002/(SICI)1097-0142(20000115)88:2<262::AID-CNCR3>3.0.CO;2-K
- Mirza IA, Shahab N (2007) Small cell cancer of the pleura, kidney, and thymus. *Semin Oncol* 34(1):67–69. doi:10.1053/j.seminoncol.2006.10.030
- Miyake M, Fujimoto K, Tanaka M, Matsushita C, Tanaka N, Hirao Y (2007) A case of small cell carcinoma of the kidney. *Hinyokika Kyo* 53(4):235–240
- Nguyen LN, Maor MH, Oswald MJ (1998) Brain metastases as the only manifestation of an undetected primary tumor. *Cancer* 83(10):2181–2184. doi:10.1002/(SICI)1097-0142(19981115)83:10<2181::AID-CNCR17>3.0.CO;2-J
- Pandit N, Gonen M, Krug L, Larson SM (2003) Prognostic value of [<sup>18</sup>F]FDG-PET imaging in small cell lung cancer. *Eur J Nucl Med Mol Imaging* 30(1):78–84. doi:10.1007/s00259-002-0937-8
- Raina V, Milroy R, al-Dawoud A, Dunlop D, Soukop M (1992) Extrapulmonary small cell carcinoma of bone. *Postgrad Med J* 68(796):147–148. doi:10.1136/pgmj.68.796.147
- Remick SC, Ruckdeschel JC (1992) Extrapulmonary and pulmonary small-cell carcinoma: tumor biology, therapy, and outcome. *Med Pediatr Oncol* 20(2):89–99. doi:10.1002/mpo.2950200202
- Samli B, Celik S, Evrensel T, Orhan B, Tasdelen I (2000) Primary neuroendocrine small cell carcinoma of the breast. *Arch Pathol Lab Med* 124(2):296–298
- Samson DJ, Seidenfeld J, Simon GR, Turrisi AT 3rd, Bonnell C, Ziegler KM, Aronson N, American College of Chest Physicians (2007) Evidence for management of small cell lung cancer: ACCP evidence-based clinical practice guidelines (2nd edition). *Chest* 132(3 Suppl):314S–323S. doi:10.1378/chest.07-1384
- Sengoz M, Abacioglu U, Salepci T, Eren F, Yumuk F, Turhal S (2003) Extrapulmonary small cell carcinoma: multimodality treatment results. *Tumori* 89(3):274–277
- Serizawa T, Ono J, Ichi T, Matsuda S, Sato M, Odaki M, Hirai S, Osato K, Saeki N, Yamaura A (2002) Gamma knife radiosurgery for metastatic brain tumors from lung cancer: a comparison between small cell and non-small cell carcinoma. *J Neurosurg* 97(5 Suppl):484–488
- Simmons NE, Elias WJ, Henson SL, Laws ER (1999) Small cell lung carcinoma causing epidural hematoma: case report. *Surg Neurol* 51(1):56–59. doi:10.1016/S0090-3019(97)00450-3
- Simon GR, Turrisi A, American College of Chest Physicians (2007) Management of small cell lung cancer: ACCP evidence-based clinical practice guidelines (2nd edition). *Chest* 132(3 Suppl):324S–339S
- Simon GR, Wagner H, American College of Chest Physicians (2003) Small cell lung cancer. *Chest* 123(1 Suppl):259S–271S. doi:10.1378/chest.123.1\_suppl.259S
- Slotman B, Faivre-Finn C, Kramer G, Rankin E, Snee M, Hatton M, Postmus P, Collette L, Musat E, Senan S, EORTC Radiation Oncology Group and Lung Cancer Group (2007) Prophylactic

- cranial irradiation in extensive small-cell lung cancer. *N Engl J Med* 357(7):664–672. doi:[10.1056/NEJMoa071780](https://doi.org/10.1056/NEJMoa071780)
36. Soto DE, Eisbruch A (2007) Limited-stage extrapulmonary small cell carcinoma: outcomes after modern chemotherapy and radiotherapy. *Cancer J* 13(4):243–246. doi:[10.1097/PPO.0b013e31813ffe7c](https://doi.org/10.1097/PPO.0b013e31813ffe7c)
37. Sundstrøm S, Bremnes RM, Kaasa S, Aasebø U, Hatlevoll R, Dahle R, Boye N, Wang M, Vigander T, Vilsvik J, Skovlund E, Hannisdal E, Aamdal S, Group. NLCS (2002) Cisplatin and etoposide regimen is superior to cyclophosphamide, epirubicin, and vincristine regimen in small-cell lung cancer: results from a randomized phase III trial with 5 years' follow-up. *J Clin Oncol* 20(24):4665–4672. doi:[10.1200/JCO.2002.12.111](https://doi.org/10.1200/JCO.2002.12.111)
38. Weiss MD, deFries HO, Taxy JB, Braine H (1983) Primary small cell carcinoma of the paranasal sinuses. *Arch Otolaryngol* 109(5):341–343